

Medical Image Analysis: Introduction

Course: CSE/EE 577

Instructor: Prof. Linda Shapiro



TA: Shu Liang



Web Page: <http://www.cs.washington.edu/577>

Related Texts

- Shapiro and Stockman, Computer Vision, Prentice-Hall, 2001.
Original chapters available at
<http://www.cs.washington.edu/education/courses/cse576/99sp/book.html>
- Dhawan, Medical Image Analysis, Second Edition, IEEE Press, 2011.
You can access this book through UW Libraries on a UW computer
or using your UW Netid.

List of Topics

- Introduction to Medical Imaging Modalities and Applications
- Low-level Operations for Processing and Enhancement
- CT Imaging
- PET/CT Registration
- Brain Imaging
 - MRI
 - fMRI
 - DTI
- Ultrasound Imaging
- 3D from Multi-Camera Stereo for Craniofacial Application
- Cancer Biopsy Processing

Evaluation

- Several Matlab programming assignments
- Course project of your choice

Some Lecture Slides will Come From

Medical Image Analysis

Atam P. Dhawan, Ph.D.

Dept. of Electrical & Computer Engineering

Dept. of Biomedical Engineering

New Jersey Institute of Technology

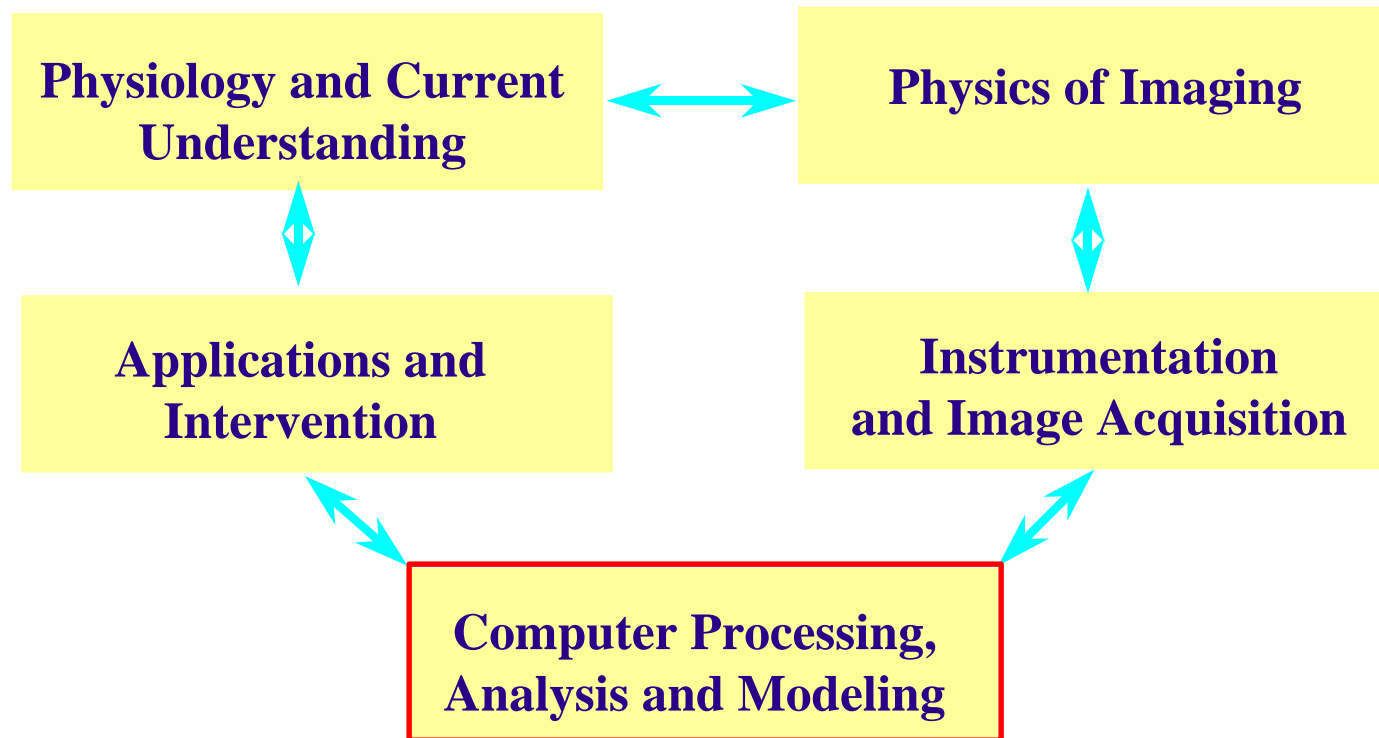
Newark, NJ, 07102

Dhawan@adm.njit.edu

Introduction

- Imaging is an essential aspect of medical sciences for
 - visualization of anatomical structures
 - functional or metabolic information of the human body
- Structural and functional imaging of human body is important for understanding
 - human body anatomy
 - physiological processes
 - function of organs
 - behavior of whole or a part of organ under the influence of abnormal physiological conditions or a disease

A Multidisciplinary Paradigm



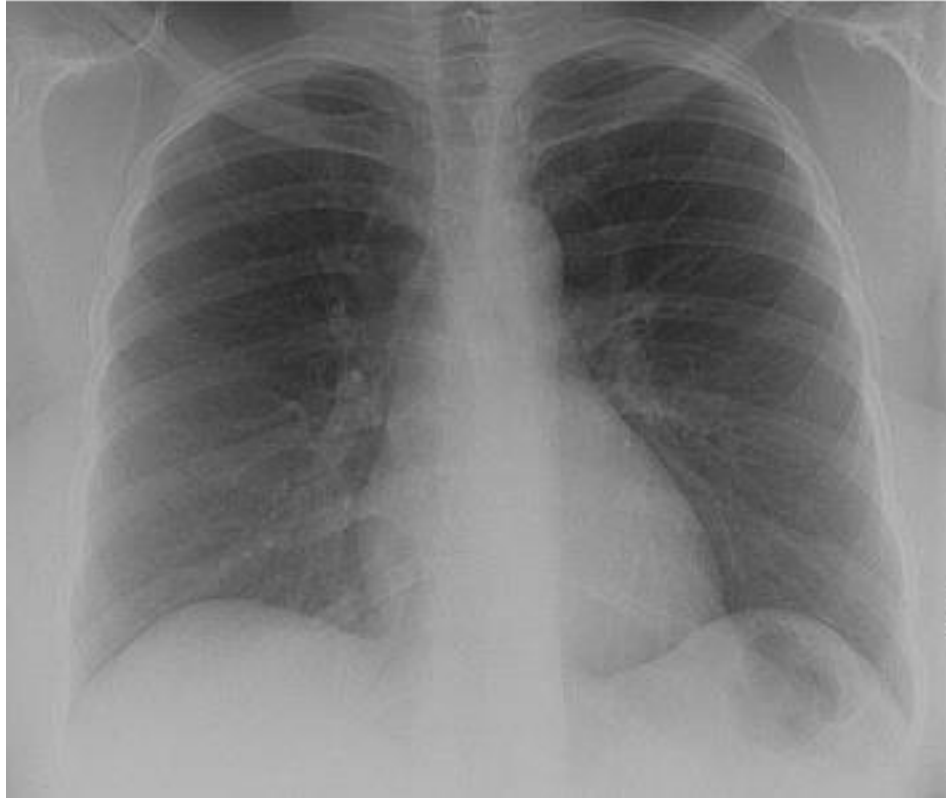Medical Imaging Information

- Anatomical
 - X-Ray Radiography
 - X-Ray CT
 - MRI
 - Ultrasound
 - Optical
 - 3D Mesh from Stereo
- Functional/Metabolic
 - SPECT
 - PET
 - fMRI, pMRI
 - Ultrasound
 - Optical Fluorescence
 - Electrical Impedance

X-rays

- X-rays were invented by Conrad Rontgen in 1895 describing it as new kind of rays which can penetrate almost anything. He described the diagnostic capabilities of X-rays for imaging the human body and received the Noble Prize in 1901.
- X-ray radiographs are the simplest form of medical imaging through the transmission of X-rays through the body which are then collected on a film. The attenuation or absorption of X-rays is described by the photoelectric and Compton effects providing more attenuation through bones than soft tissues or air.

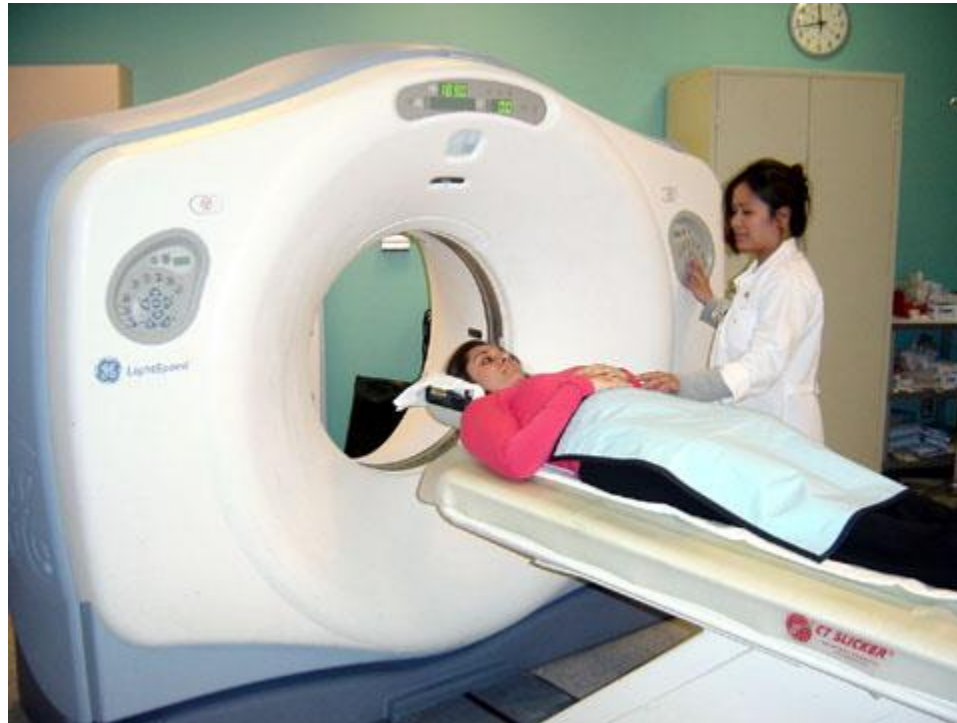Chest Radiograph



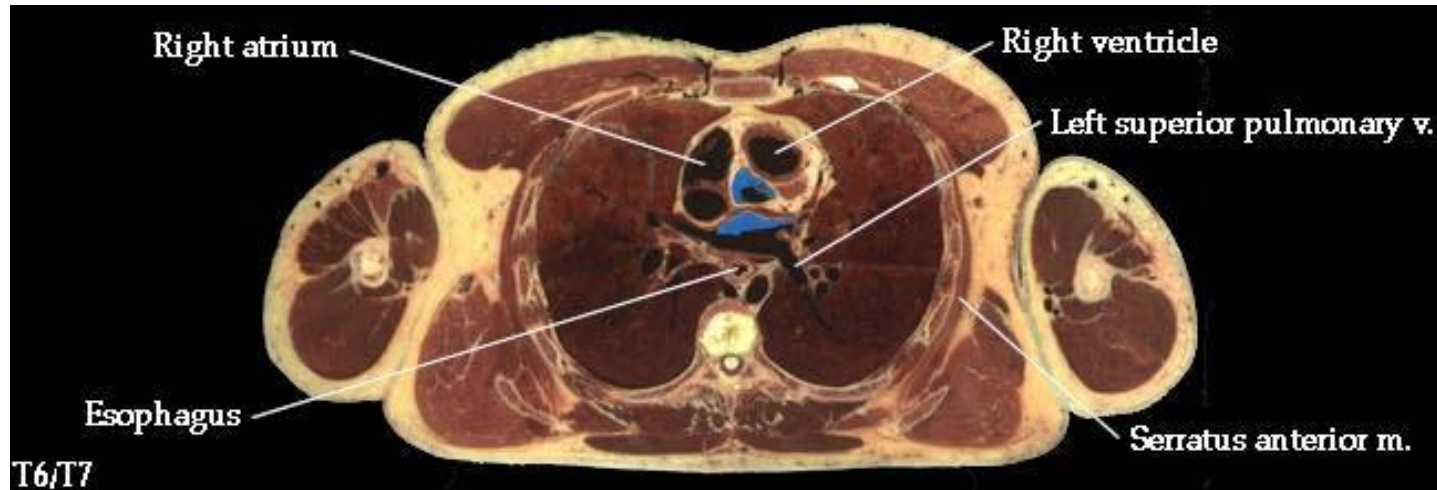
Computed Tomography

- radiography in which a **three-dimensional image of a body structure** is constructed by computer from a series of plane cross-sectional images made along an axis
- also called computed axial tomography, computerized axial tomography, computerized tomography

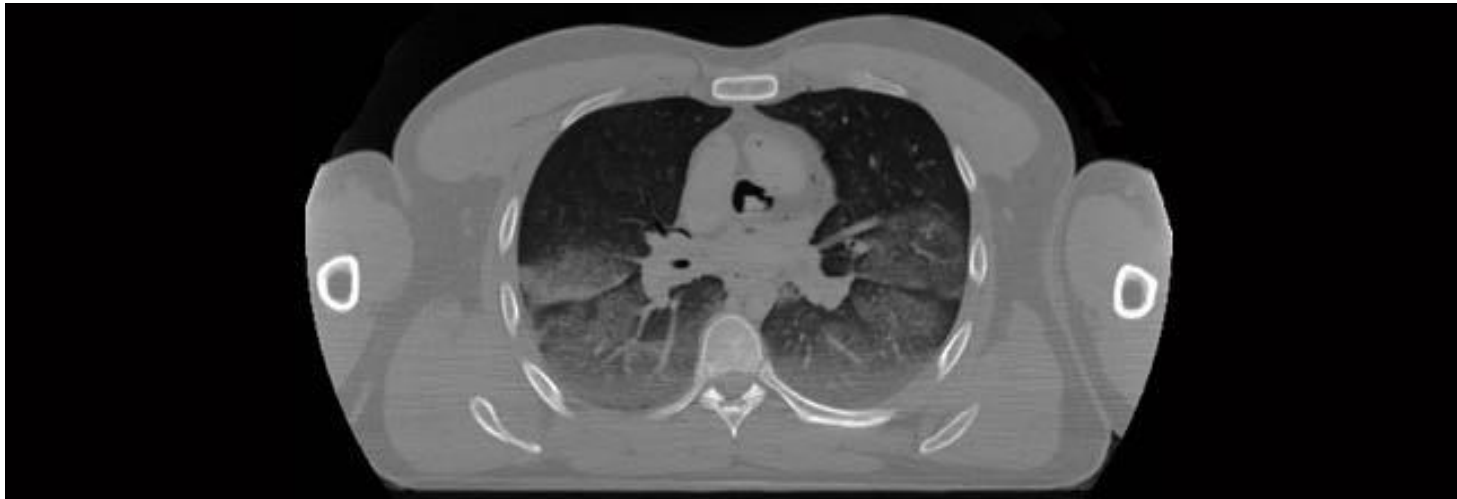CT Scanner



CT Chest Images



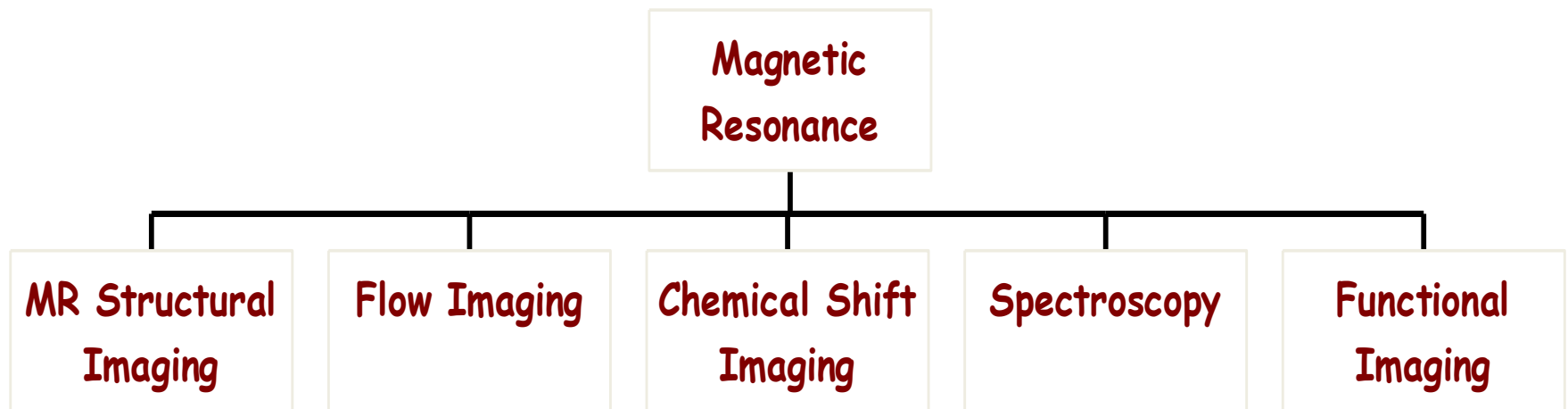
pathological
image of a slice
of the cardiac
cavity of a
cadaver.



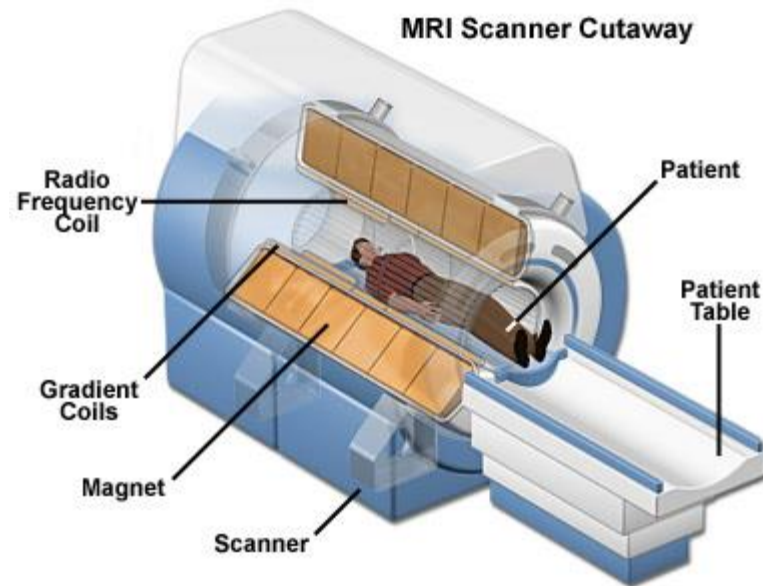
X-ray CT image
of the same
slice

Magnetic Resonance Imaging

Basic Principle: The electromagnetic induction based rf signals are collected through nuclear magnetic resonance from the excited nuclei with magnetic moment and angular momentum present in the body. Most common is proton density imaging.

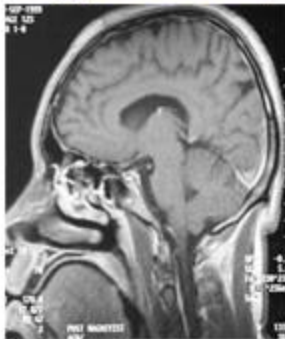


MRI Scanner

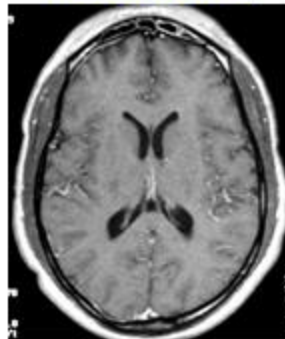


3-D Brain Imaging

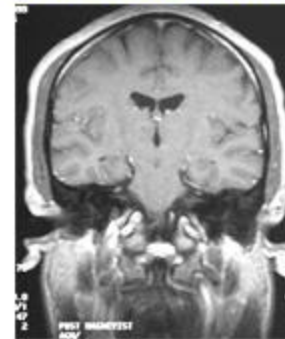
Sagittal View



Axial View



Coronal View



[Anatomy Modules Home](#)

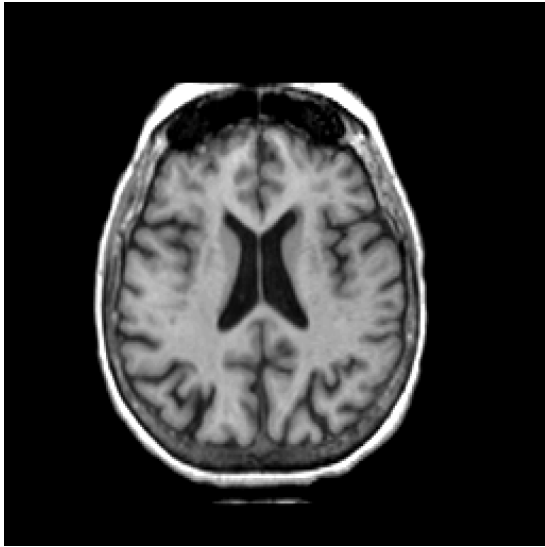
Developed by Jeffrey E. Zapawa and Anthony L. Alcantara, MD

left-right

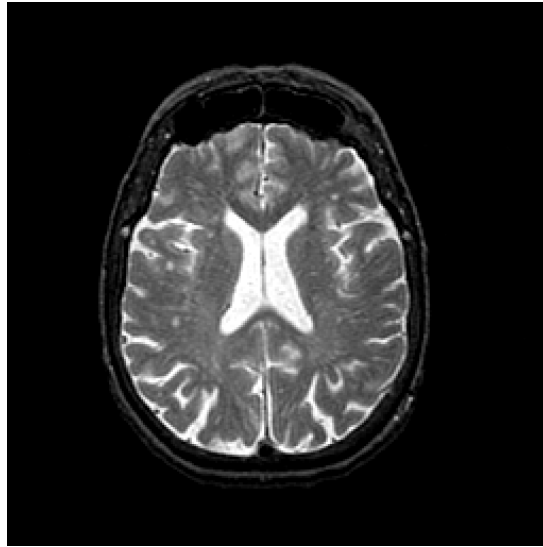
top-bottom

front-back

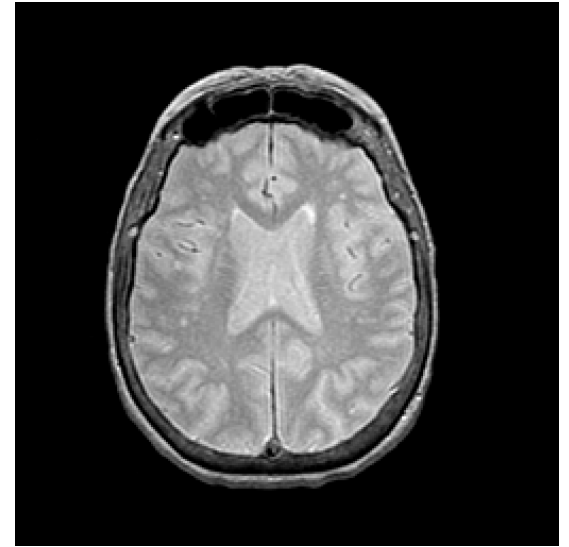
Kinds of MR Images



T1 Weighted



T2 Weighted



Spin Density Image

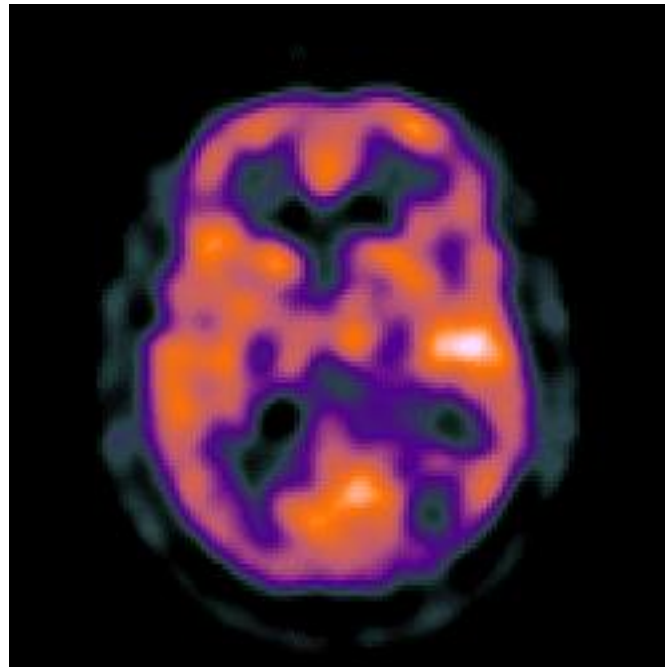
MRI Advantage

- The most important advantage of the MRI is its ability to provide unprecedented **contrasts** between various organs and tissues and the three-dimensional nature of imaging methods.
- Selective 3-D imaging is provided by appropriate selection of gradient fields and phase encoding methods.
- A variety of contrast images can be created by different combinations of weighting of T1, T2 and echo images
- MR spectroscopy provides a great potential for meaningful tissue characterization.
- **Functional MRI holds great promise for the future.**

SPECT

- Radioactive materials are administered into the body and are selectively taken up in a manner designed to indicate a specific metabolism or disease.
- In SPECT imaging, gamma rays are emitted from these materials absorbed by the tissue or body, which then becomes a radioactive source. External detectors are used to reconstruct images of the radioactive source.

^{99m}Tc (140 keV) SPECT Image



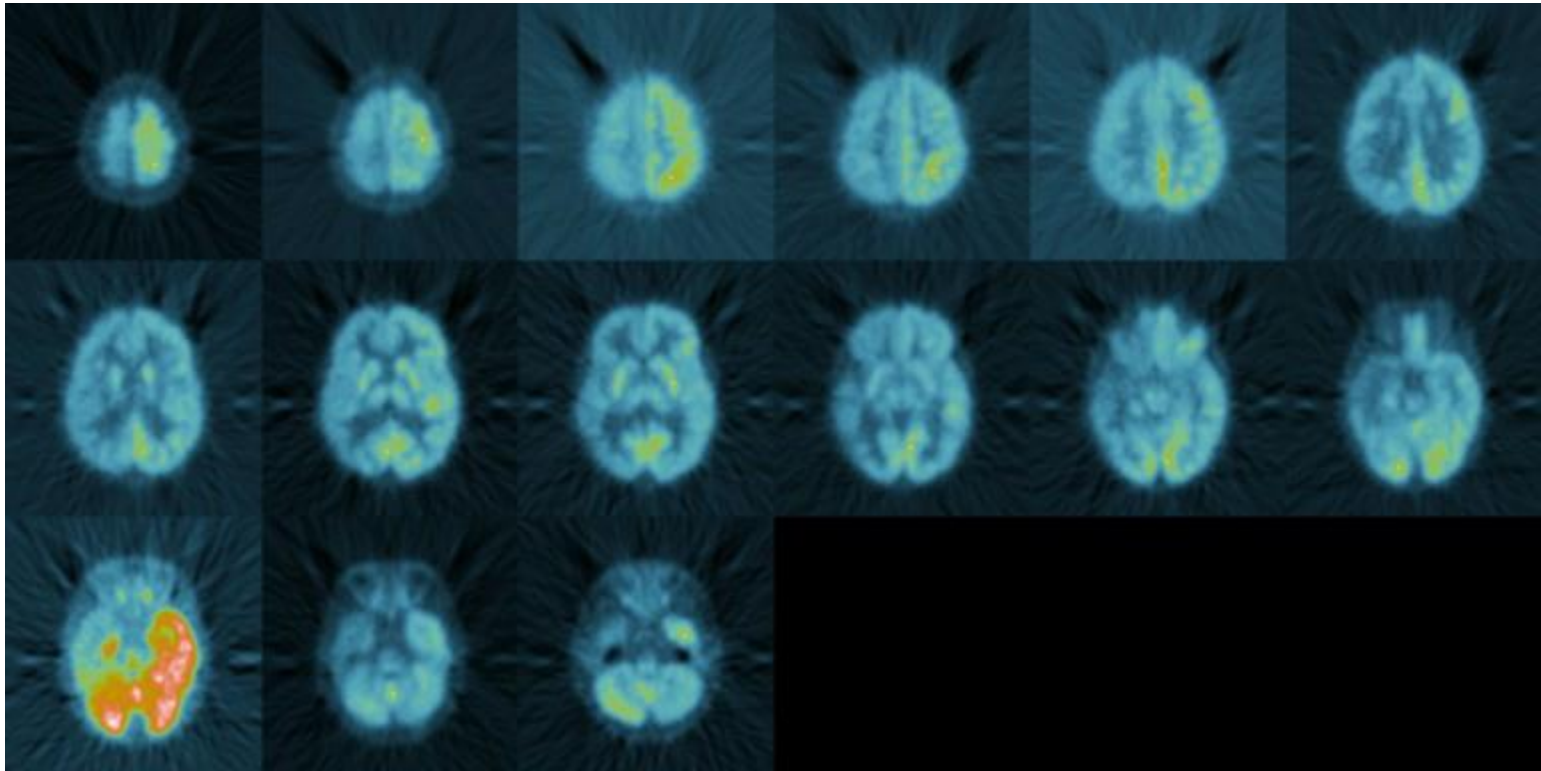
PET

- In PET imaging, the radioactive pharmaceuticals which decay by **emitting positrons** are administered in the body.
- When these radioactive materials are taken up by the body, positrons are emitted which, after losing some energy through kinetic motion, annihilates with the free electrons of the biomaterial within the body.
- The annihilation results in the emission of two photons, which travel in almost opposite directions and escape from the body to be detected by external detectors. This is called the **coincidence detection**.

PET

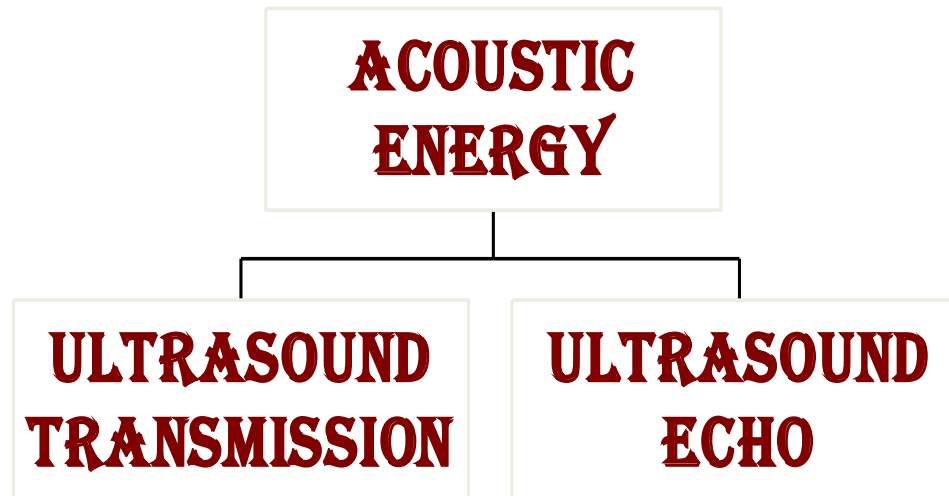
- In PET, **images** are reconstructed from the coincidence detection to **represent the distribution of the emission of photons within the body**.
- Since the emission of photons is very close to the emission of positron, the reconstructed images are considered the representation of the radioactivity source or tracer.

FDG PET Imaging



Ultrasound Imaging

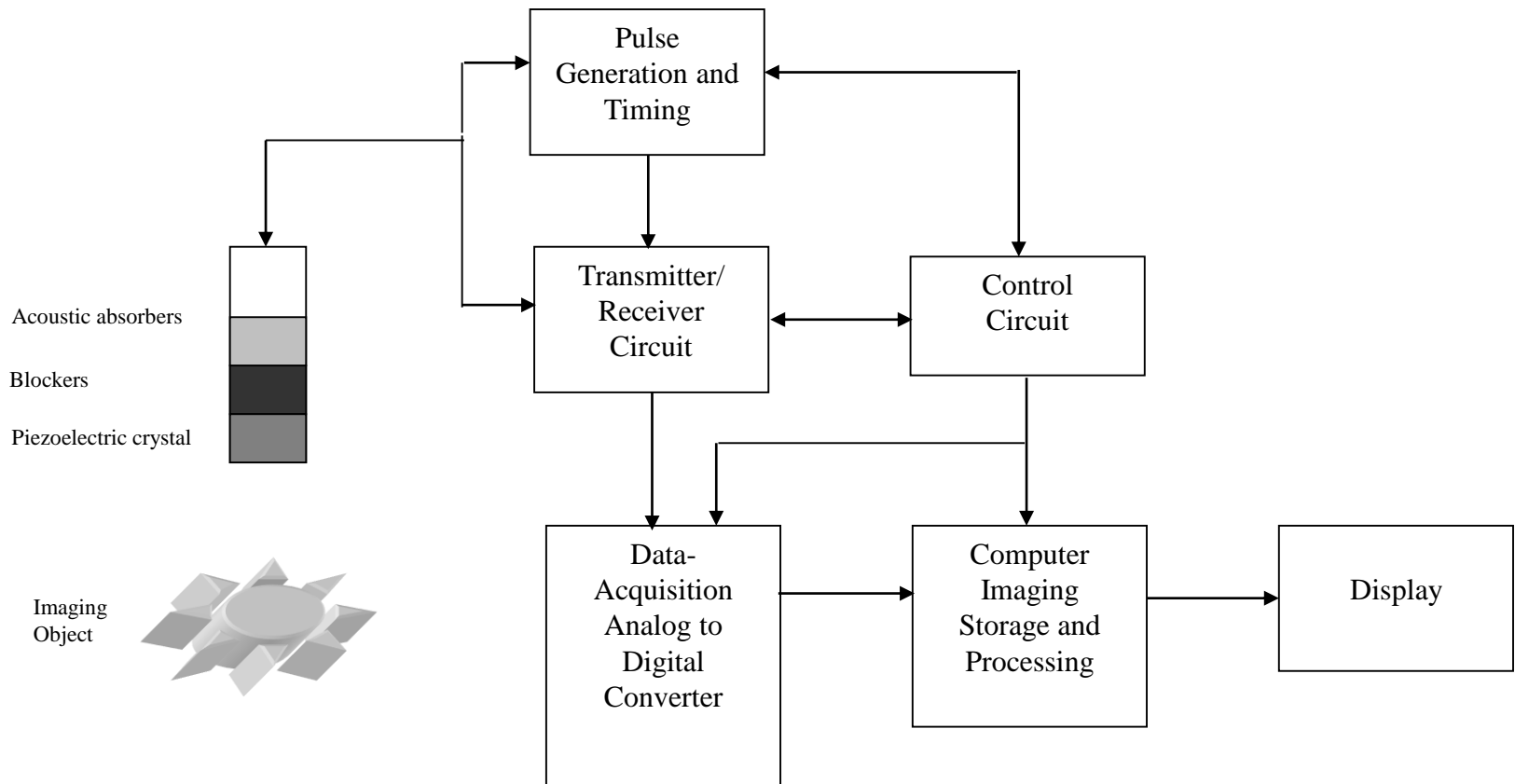
Basic Principle: Backscattered echo and Doppler shift principles are more commonly used with the interaction of sound waves with human tissue. Sometimes the scattering information is complemented with transmission or attenuation related information such as velocity in the tissue.



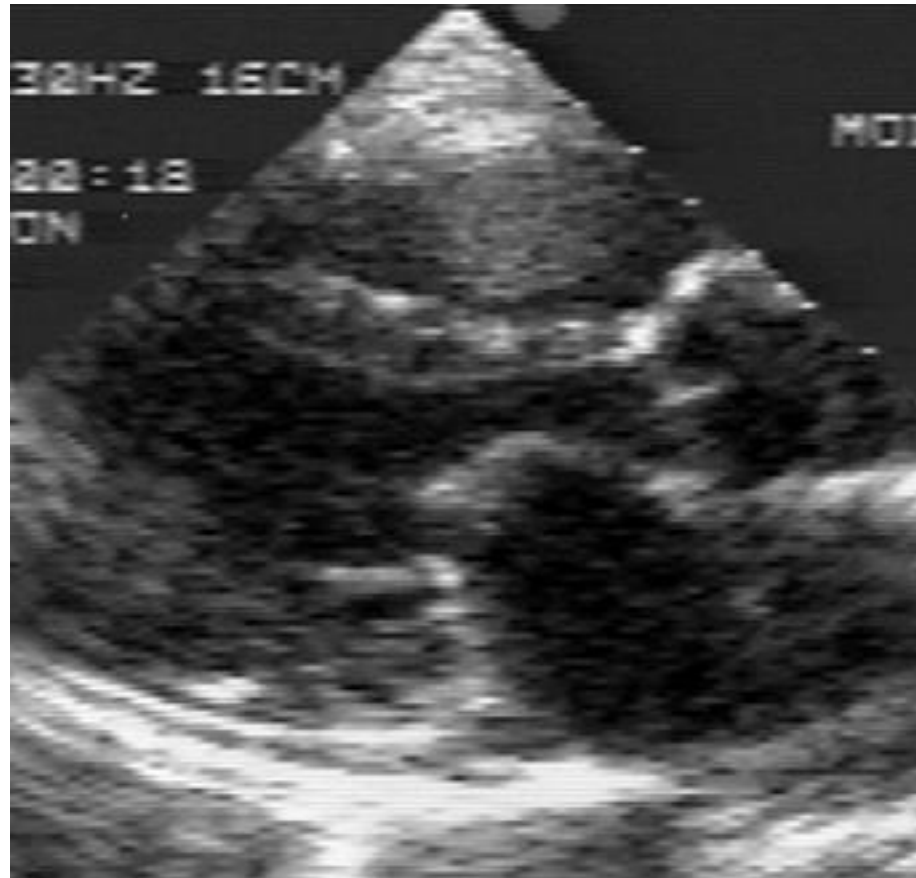Ultrasound Imaging

- For thicker parts of the body such as abdominal imaging, frequencies of about 1.0 to 3.0 MHz are used to provide reasonable attenuation.
- Unlike X-rays, in ultrasound imaging, the images are produced through the reflection or echo using the known velocity of propagation to calculate the depth.
- In ultrasound imaging, air causes excessive attenuation and therefore cannot be used to study some anatomical structures, such as lungs.
- Ultrasound imaging operates close to the diffraction limit because of its larger wavelength compared to X-rays.

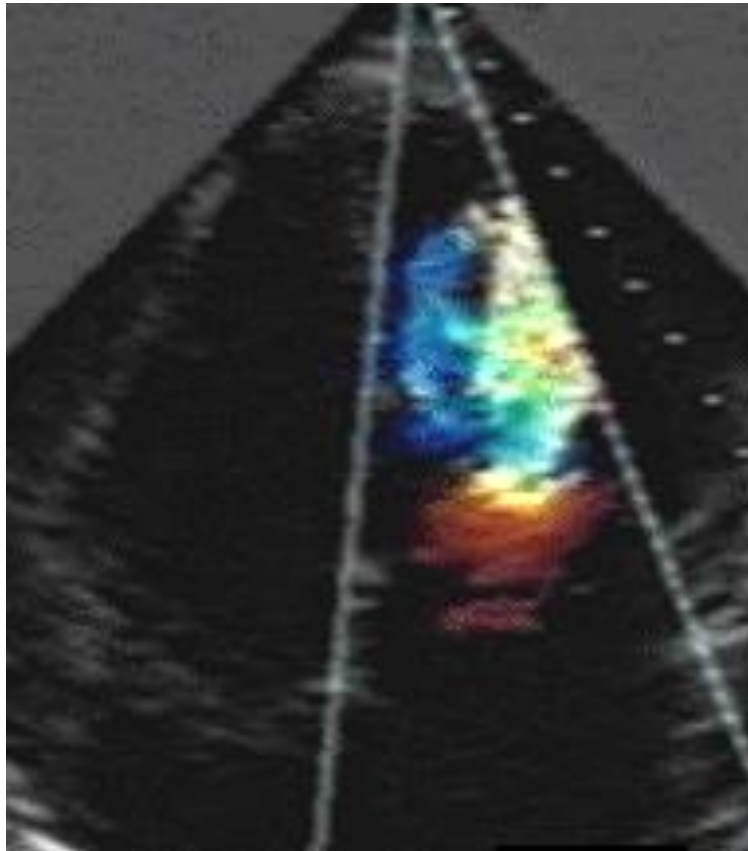
Ultrasound Imaging



B-Mode Imaging of Heart



Doppler Imaging of Beating Heart

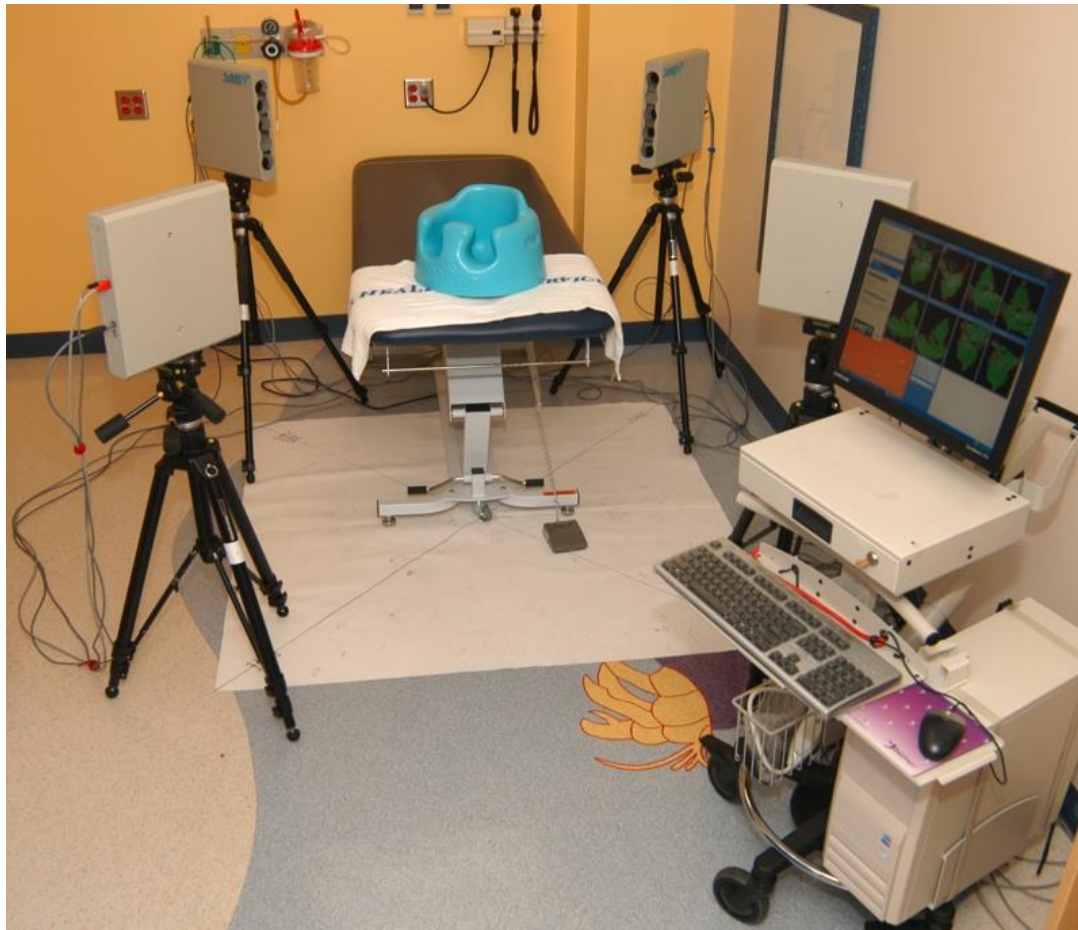

Ultrasound Advantage


- The main advantage of ultrasound imaging is its **non-invasive nature** and capability of providing excellent information for imaging objects **immersed in fluids**.
- Another advantage of using ultrasound is its low velocity of propagation as compared to the free-space velocity of X-rays which is 3×10^8 m/sec. This makes **the time of flight measurements** possible using ultrasound with pulse echo techniques.
- Unlike X-rays, the velocity of propagation of ultrasound is dependent on the material. Ultrasound provides a variety of refractive indices of materials. Thus, **selective imaging of specific planes** is feasible with ultrasound through the construction of so-called lens systems to provide images of focused structures.

3D from Stereo

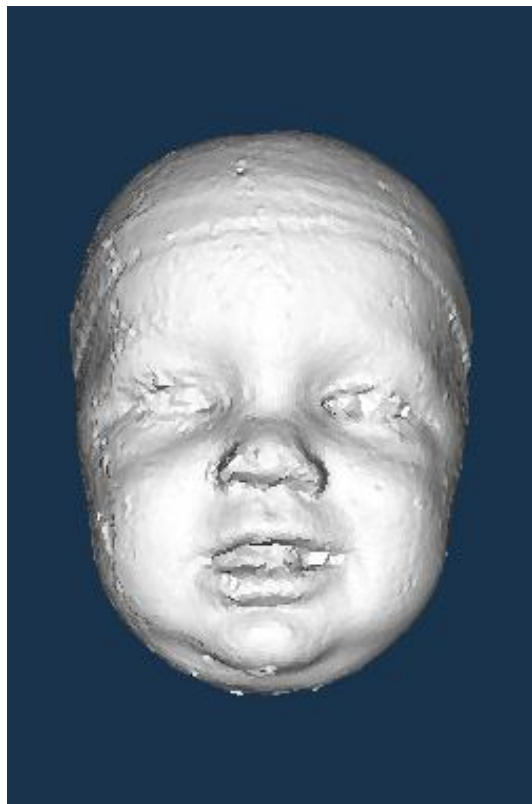3dMD 12-Camera Stereo System at Children's Hospital



3D Mesh from 3dMD




Some Sample Head Meshes



10 months



10 years



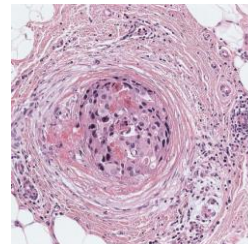
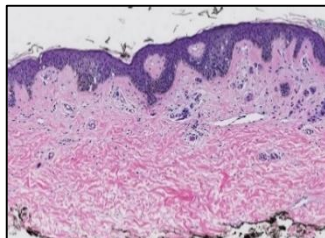
30 years

Advantages

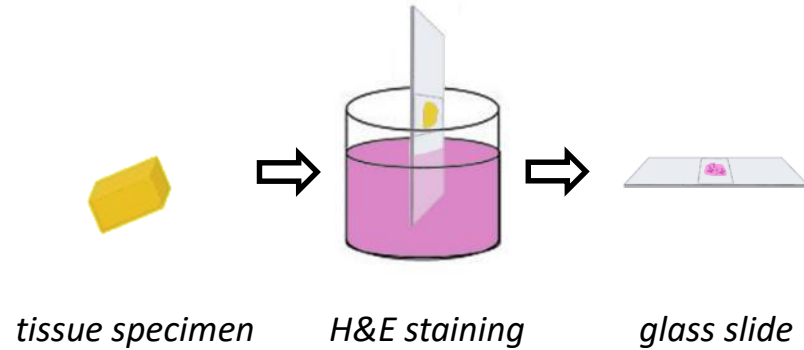
- Allows for 3D head images of young children since the **image acquisition is very fast**
- **3D mesh format** is common in computer vision so there are many known algorithms
- Can be analyzed in mesh format or converted to other forms such as a 3D depth image

Digital Pathology

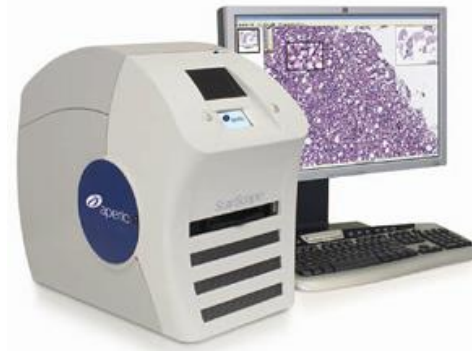- After an image from a machine shows possible cancer, physicians perform a **biopsy**.
- Pathologists look at the biopsy, traditionally on a **slide under a microscope**.
- Now, the FDA has approved **digital pathology**, and our group is working on both **breast** and **melanoma** cancer biopsy analysis.



Medical Diagnosis of Cancer

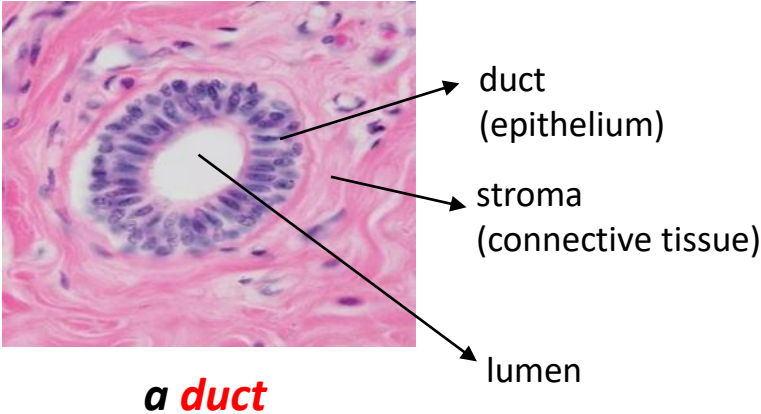
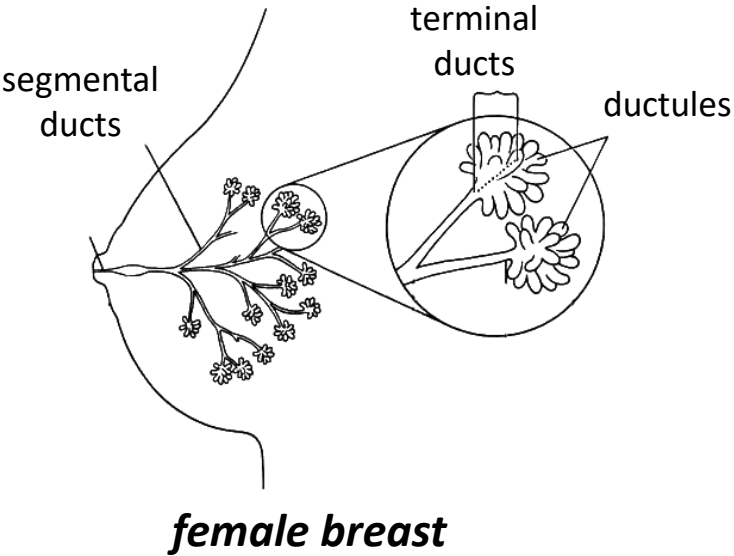


light microscope

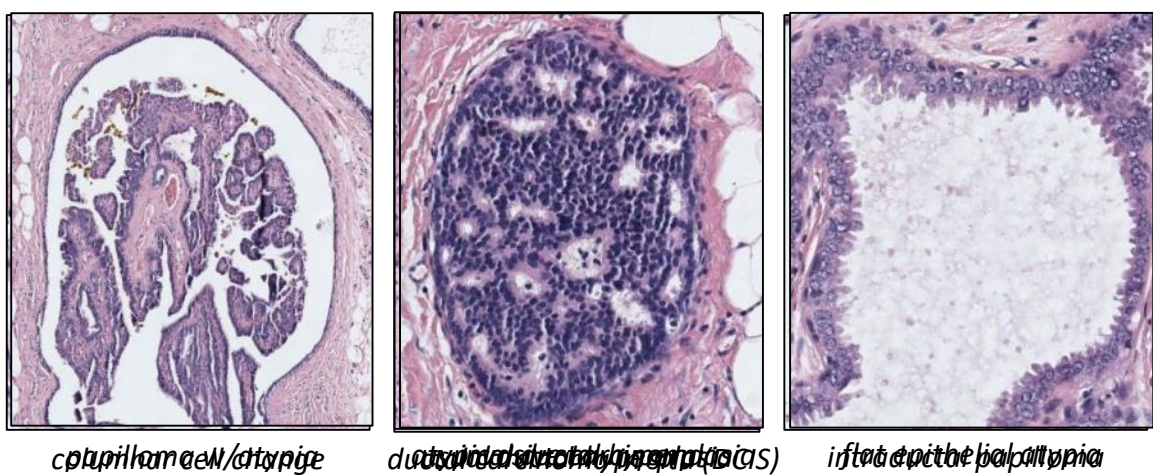
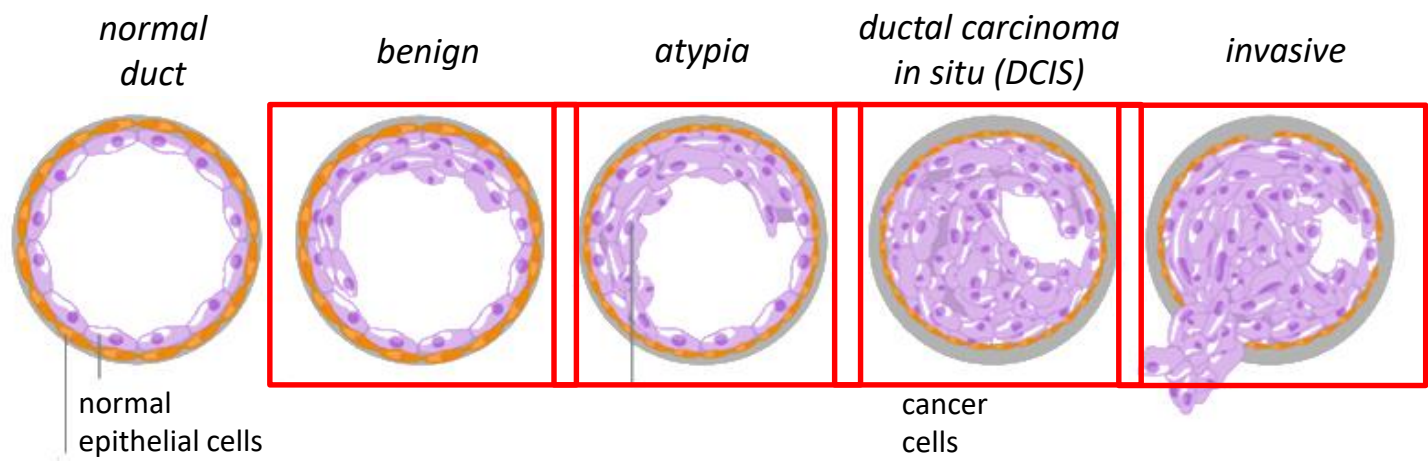


whole slide imaging

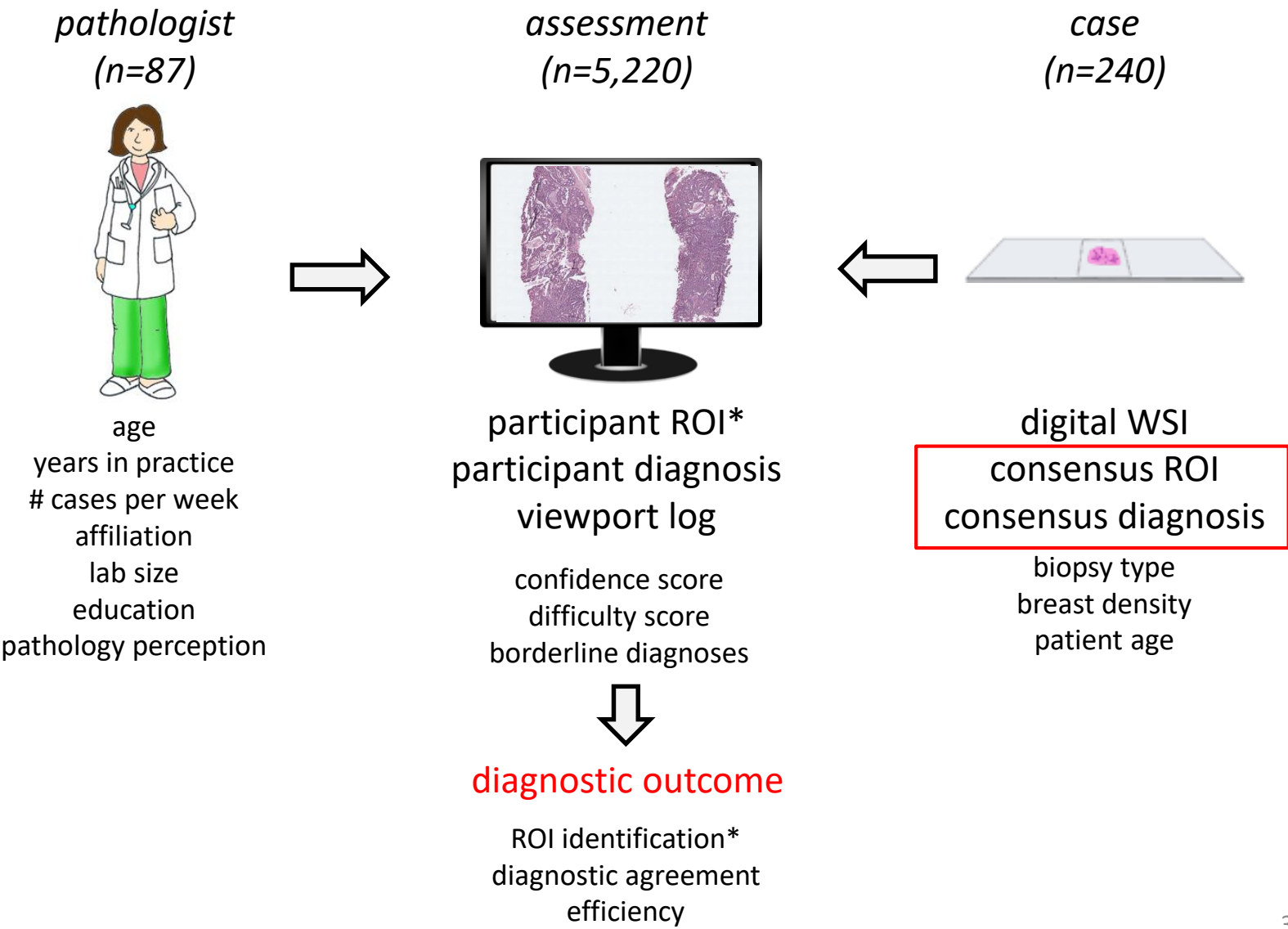
Breast Histopathology



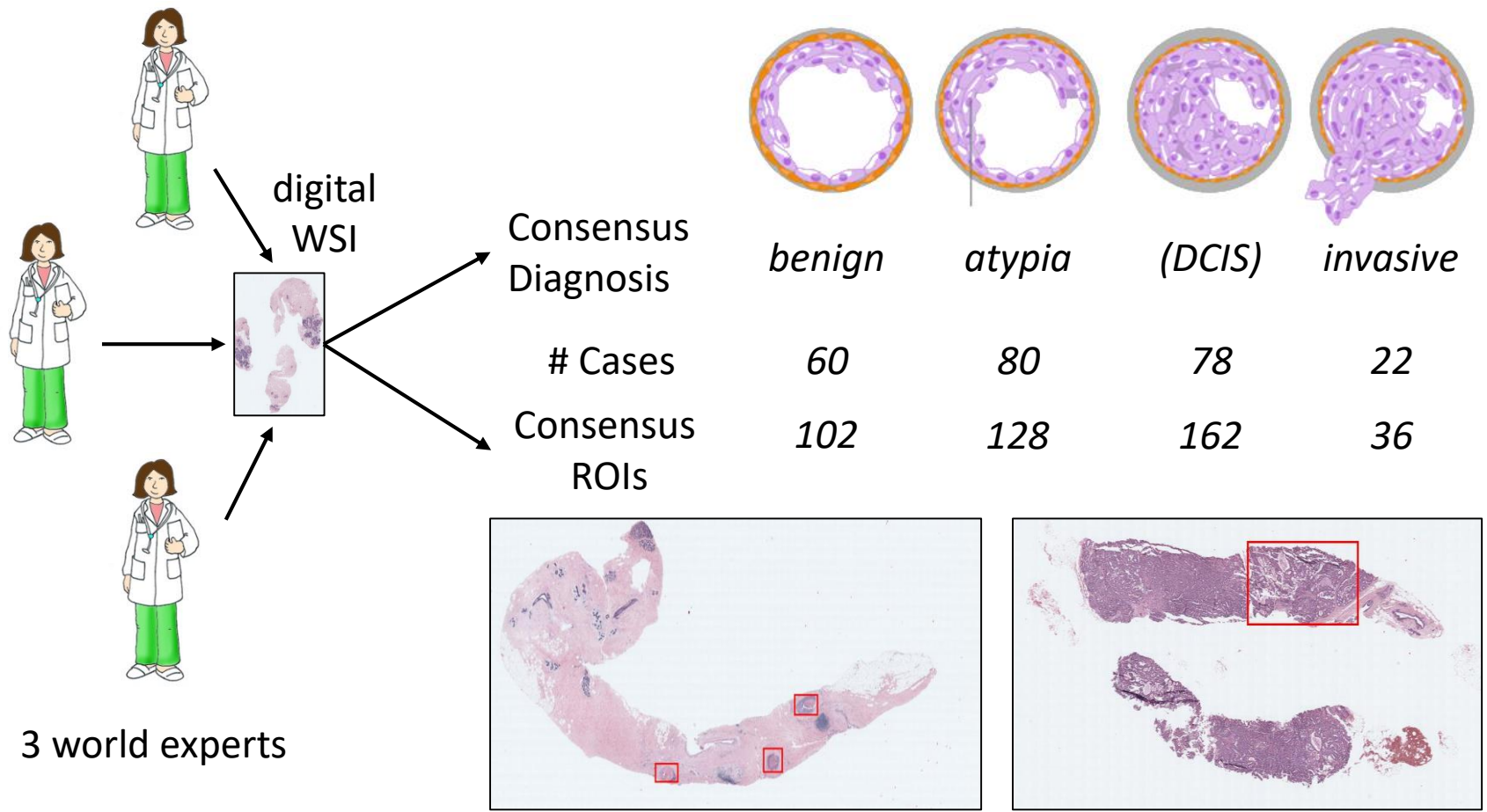
Diagnostic Categories



digiPATH Dataset



Expert Consensus Data Collection



Epilogue

- There are multiple imaging modalities, each with its own characteristics.
- When I started to work here, a radiologist told me they would **never** use digital images.
- **Now they only use digital images** and automation is an important topic.
- In April 2017 Philips obtained FDA approval for use of whole slide digital images, beginning a **new era for pathologists**.